

PATIENT

Wheezie Fisher

SPECIES

Feline

BREED

DSH

SEX

Neutered Male

AGE

14 years

WEIGHT

12 lbs

INTERPRETED BY

Andrea Nicastro, DVM,
Diplomate ACVIM
(Small Animal Internal
Medicine)

IMAGING PERFORMED BY

Amy Mayhew LVT

HOSPITAL NAME

SVS Imaging Michigan

REFERRING VET

Dr. Kelli Collard

INVOICE

12290

DATE

2.27.23

PRESENTING CLINICAL SIGNS

History: Not eating

Abnormal PE/Chem/CBC/UA Results: Fatty liver and gallbladder issues, suspecting mild pancreatitis as well. Extremely icteric.

ULTRASONOGRAPHIC EXAMINATION OF THE ABDOMEN

Urinary System

The urinary bladder, trigone, and pelvic urethra are normal in thickness and the mucosal surface is smooth. The bladder lumen is moderately distended. A small amount of suspended echogenic debris is observed within the lumen. No masses, inflammatory changes or calculi are observed. The region of the trigone is normal. There are questionable urethroliths in the proximal urethra. The visible of the urethral lumen is not overtly dilated.

The left kidney is normal in size (4.50 cm in length) with a normal shape, architecture and smooth peripheral margins. The cortex is isoechoic relative to the spleen. There is a normal 1:3 cortex to medulla ratio with minimal to mild loss of corticomedullary distinction. Several nonobstructive nephroliths are visualized. There is no evidence of pyelectasia, infarcts or hydroureter.

The right kidney is normal in size (4.50 cm in length) with a normal shape, smooth peripheral margins, and normal internal architecture. The cortex is isoechoic relative to the spleen. There is mild loss of corticomedullary distinction. Several hyperechoic shadowing diverticular foci are observed. Trace pyelectasia is present. There is no evidence of infarcts or hydroureter.

Adrenal Glands

The left adrenal gland is enlarged (0.94 cm width) with a rounded shape. Glandular echogenicity and detail are normal. Surrounding vasculature appears normal.

The right adrenal gland is normal size (0.38 cm width). Normal shape and glandular echogenicity. The phrenicoabdominal vein and surrounding vasculature are normal.

Spleen

The spleen is normal in size (0.90 cm in width at the level of the hilus) with a normal capsular contour. There is appropriate echogenicity and echotexture. No focal lesions are observed. Splenic vasculature is normal.

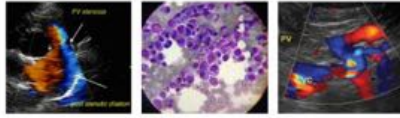
Liver

The liver is subjectively enlarged with slightly swollen peripheral contours. The parenchyma is isoechoic relative to the spleen and diffusely homogeneous in appearance. No distinct focal lesions are observed. Vascular and biliary tracts are of normal volume with no evidence of congestion.

The gall bladder is distended. The wall is normal in thickness. A small to moderate amount of aggregated, echogenic, partially dependent debris/sludge is observed within the lumen. The cystic and common bile ducts are tortuous and dilated. The common bile duct measures up to 0.56 cm in diameter. In the distal aspect of the common bile duct lumen, an approximately 0.75 cm echogenic structure is observed. The duodenal papilla itself is normal in size (0.38 cm in width).

Gastrointestinal

The stomach and intestine are free of stasis and exhibit normal peristaltic activity. The gastric lumen is not distended. The gastric wall and pylorus are normal in thickness with a normal layering pattern. The pyloric outflow tract is patent. The small intestinal lumen is not dilated. The small intestinal wall thickness is normal with a normal layering pattern and appropriate mural detail. There is disruption in the normal 1:3 muscularis: mucosal ratio in some segments. Discreet masses are not identified. The ileocecal colic junction and colonic wall are normal. No obstructive disease is noted.

**PATIENT**

Wheezie Fisher

SPECIES

Feline

BREED

DSH

SEX

Neutered Male

AGE

14 years

WEIGHT

12 lbs

INTERPRETED BY

Andrea Nicastro, DVM,
Diplomate ACVIM
(Small Animal Internal
Medicine)

IMAGING PERFORMED BY

Amy Mayhew LVT

HOSPITAL NAME

SVS Imaging Michigan

REFERRING VET

Dr. Kelli Collard

INVOICE

12290

DATE

2.27.23

Pancreas

The pancreas is diffusely prominent to enlarged, with irregular peripheral contours. The parenchyma is hypoechoic relative to surrounding omental fat and mottled in appearance, with several small cystic areas, as well as a slight nodular appearance in the region of the left limb. The pancreatic parenchyma appears to meld with the distal common bile duct. The pancreatic duct is dilated (up to 0.28 cm in diameter). Surrounding mesentery is slightly hyperechoic.

Free Abdomen

There is no obvious evidence free fluid. A few prominent mesenteric lymph nodes are visualized (the largest measuring 1.53 cm in length). Surrounding mesentery is mildly hyperechoic.

ULTRASONOGRAPHIC FINDINGS**Primary Findings**

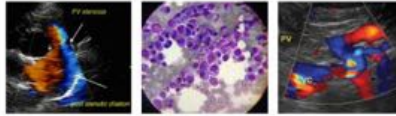
- The common bile duct changes are concerning for an obstruction at the level of the duodenal papilla. The echogenic material in the common bile duct lumen may represent mucous, an emerging tumor, or an inflammatory focus (i.e., secondary to pancreatitis or cholangitis).
- The pancreatic changes could be consistent with pancreatitis. However, an emerging tumor cannot be excluded, particularly in the region of the right limb where it appears to engulf the distal common bile duct.
- Hepatic changes are non-specific and could be consistent with hepatic lipidosis, inflammatory/infectious disease, infiltrative neoplasia, or other hepatopathy.

Secondary Findings

- Bilateral chronic renal changes with nonobstructive nephrolithiasis
- Questionable proximal urethroliths (versus artifact from the colon).
- Bowel pattern consistent with inflammatory bowel disease with some potential for emerging lymphoma.
- The prominent abdominal lymph nodes are most consistent with reactive lymphadenitis or lymphoid hyperplasia. Neoplastic infiltration is considered less likely.
- The left adrenomegaly could be consistent with stress, hyperplasia or an emerging tumor.

INTERPRETATION OF THE FINDINGS & FURTHER RECOMMENDATIONS

- Depending on the degree of hyperbilirubinemia, an abdominal exploratory with assessment of bile duct patency should be considered due to the concern for a distal common bile duct obstruction. Biopsies in this region (including the pancreas, liver, +/- common bile duct) may be warranted. GI biopsies should also be obtained at the time of surgery. If surgery is pursued, referral to a board-certified surgeon is recommended due to the potential for perioperative complications. Clotting times and thoracic radiographs should be performed prior to surgery. A temporary feeding tube may be warranted to allow for nutritional support post-operatively.
- A malabsorption panel, including serum cobalamin and folate, TLI and PLI is also recommended to assess for concurrent maldigestion/malabsorption pancreatic disease.



PATIENT

Wheezie Fisher

- To further evaluate for proximal urethroliths, consider performing abdominal radiographs or obtaining additional sonographic images of the cystourethral junction.

SPECIES

Feline

BREED

DSH

SEX

Neutered Male

AGE

14 years

WEIGHT

12 lbs

INTERPRETED BY

Andrea Nicastro, DVM,
Diplomate ACVIM
(Small Animal Internal
Medicine)

IMAGING PERFORMED BY

Amy Mayhew LVT

HOSPITAL NAME

SVS Imaging Michigan

REFERRING VET

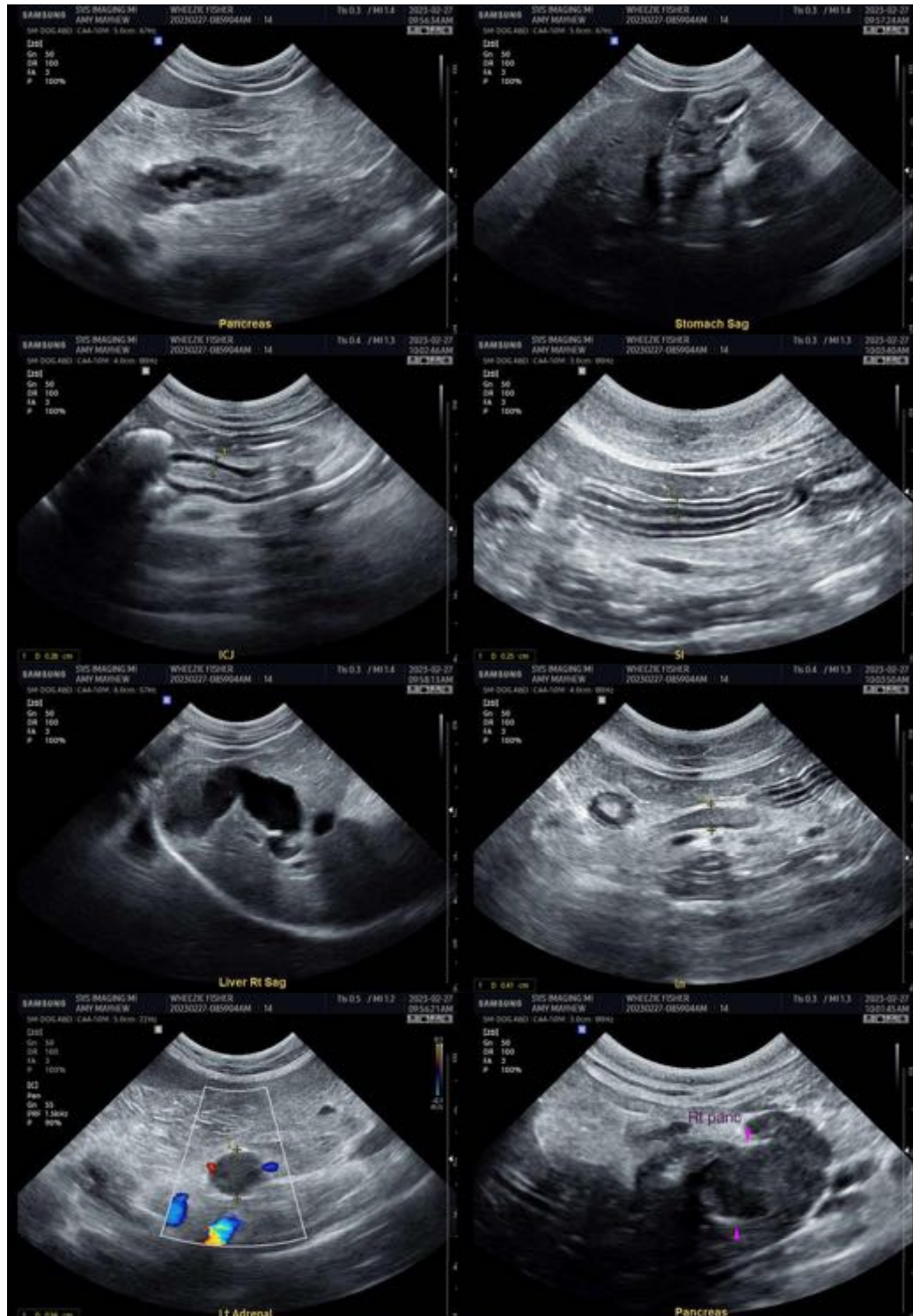
Dr. Kelli Collard

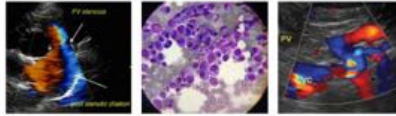
INVOICE

12290

DATE

2.27.23





PATIENT

Wheezie Fisher

SPECIES

Feline

BREED

DSH

SEX

Neutered Male

AGE

14 years

WEIGHT

12 lbs

INTERPRETED BY

Andrea Nicastro, DVM,
Diplomate ACVIM
(Small Animal Internal
Medicine)

IMAGING PERFORMED BY

Amy Mayhew LVT

HOSPITAL NAME

SVS Imaging Michigan

REFERRING VET

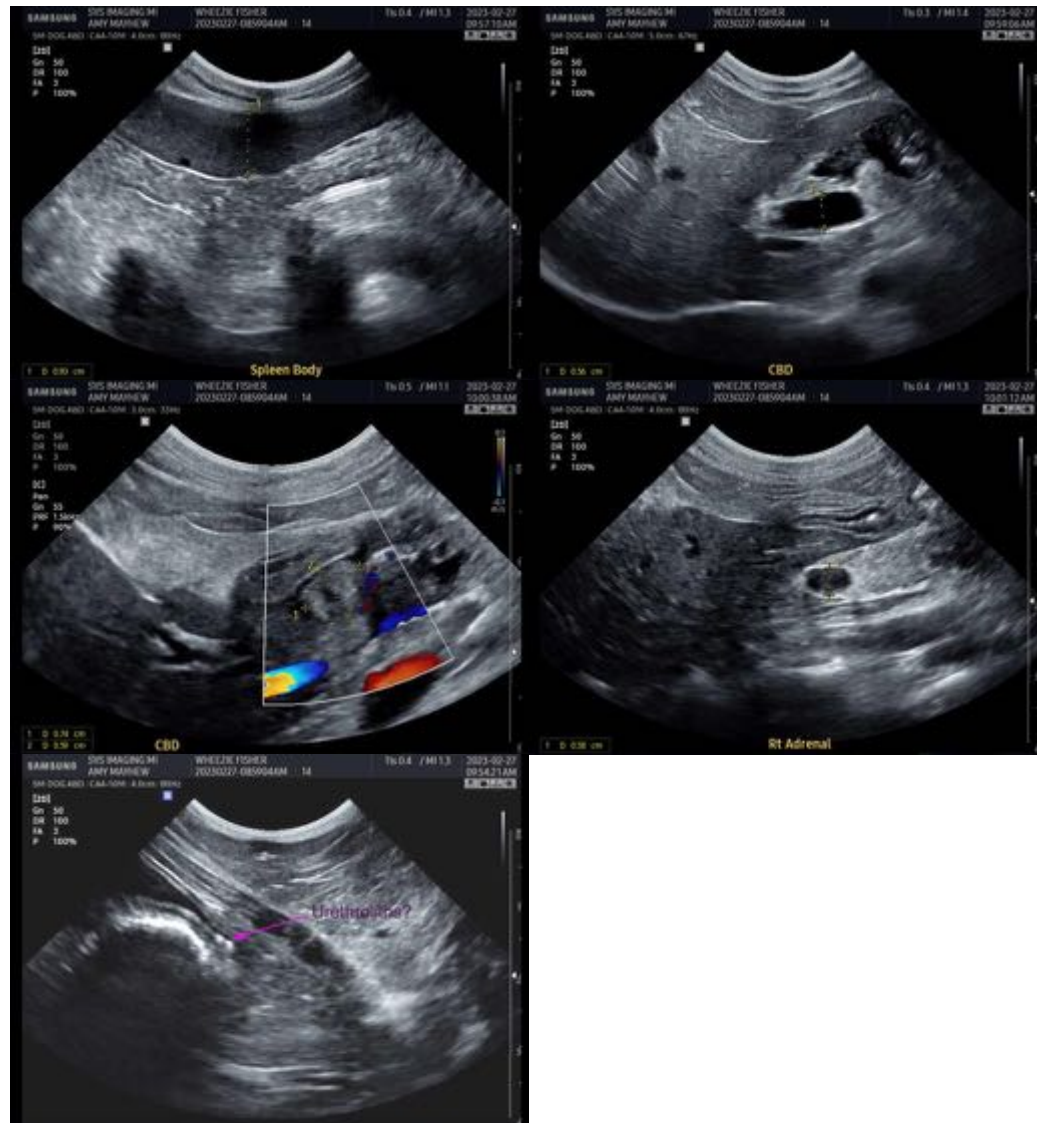
Dr. Kelli Collard

INVOICE

12290

DATE

2.27.23



The information and recommendations provided are based on the images presented by the referring veterinarian/sonographer. No evaluation can be communicated regarding pathology that was not visible in the image/video clips provided.

Thank you for this referral. If the clinical or image interpretation does not parallel your findings or if I can be of any further assistance, please contact me.

Andrea Nicastro, DVM, Diplomate DACVIM (Small Animal Internal Medicine)
info@SonoPath.com